

CLINICAL RESEARCH

SURGERY FOR ATRESIA AURIS. RETROSPECTIVE STUDY OF OUR RESULTS AND CORRELATION WITH JAHRSDOERFER PROGNOSTIC CRITERIUM

F. VÁZQUEZ DE LA IGLESIA, F. J. CERVERA-PAZ, M. MANRIQUE RODRÍGUEZ

DEPARTAMENTO DE OTORRINOLARINGOLOGÍA CLÍNICA UNIVERSITARIA, UNIVERSIDAD DE NAVARRA. PAMPLONA.

ABSTRACT

Objectives: The study goal was to evaluate the hearing follow up results in patients who underwent surgery for congenital aural atresia. We studied hearing results and correlated them with Jahrsdoerfer prognostic classification. Protocols management of unilateral and bilateral *atresia auris* are written considering to our results and other authors. *Methods:* We conducted a retrospective review of 12 ears who underwent surgery for congenital aural atresia between 1989 and 2002. CT scan was used to

evaluate Jahrsdoerfer prognostic classification and the correlation with the hearing results. *Results:* There are significant statistical differences ($p=0,003$) in air-bone gap closure before and after surgery, also a lineal significant correlation ($p=0,016$) between Jahrsdoerfer prognostic classification and air-bone gap closure. *Conclusion:* Atresioplasty surgery in individuals with congenital aural atresia can yield good hearing results in selected cases.

KEY WORDS: *Aural atresia. Jahrsdoerfer. Air-bone gap.*

Correspondence: Francisco Vázquez de la Iglesia, Departamento de Otorrinolaringología. Clínica Universitaria, Universidad de Navarra. Avda. Pío XII nº36, 31008 Pamplona. E-mail: pvazquez@unav.es

Fecha de recepción: 12-4-2004

Fecha de aceptación: 1-6-2004

INTRODUCTION

Aural atresia is defined as the symptoms caused by aplasia or hypoplasia of the external auditory canal (EAC); the absence, or deformation of the earlobe (microtia/anotia); and the presence of anatomical changes in the middle ear and occasionally in the inner ear¹. It is estimated that annually one baby in 10,000 to 20,000 is born with aural atresia², being unilateral aplasia three times more common than the bilateral form. The degree of deformity of the earlobe and of the EAC generally correlate with a more serious malformation of the middle ear³: only 4% of middle and external ear malformations are associated with changes in the inner ear¹. In 5% cases of aural atresia, this deformity forms part of a multiple malformation syndrome, the most common ones being the Treacher Collins and Klippel-Feil⁴ syndromes.

In order to decide the most appropriate treatment for aural atresia, exhaustive knowledge of the degree of the malformation of the middle ear and of the functionality of the inner ear is important. For this reason, exact radiological and audiometric evaluations are essential in the assessment of patients with aural atresia. These are done by means of high-resolution computed tomography imaging (CT scans) of the petrous apex and with either tonal audiometry or with auditory brainstem evoked potentials. Thus, the morphological and functional integrity of the inner ear is of great importance in order to carry out a more or less guaranteed successful surgical repair. We have used the classification proposed by Jahrsdoerfer¹, between all the different existing ones for aural atresia.

This is classification of different anatomical aspects of the temporal bone and is done using axial and coronal planes in CT scans (Table 1). This classification aims to be a prognosis guide regarding the probable success of any surgery prescribed.

We have made a retrospective study of the aural atresia cases treated with surgery in our center, comparing the auditory results from before and after surgery and correlating them with the points obtained from the Jahrsdoerfer classification. Here we will present this data and discuss the complications that arose in the ears that were operated on as well as propose a diagnosis and therapy protocol that can be used for the selection of patients with aural atresia.

Table 1: Jahrsdoerfer Classification

PARAMETER	POINTS	SCORE	CANDIDATE
Stirrup bone present	2	10	Excellent
Open oval window	1	9	Very good
Middle ear space	1	8	Good
Facial nerve normal	1	7	Regular
Hammer and anvil present	1	6	Borderline
Well-pneumatized mastoids	1	5 or less	Bad
The incudo-stapedial joint	1		
Round window normal	1		
Presence of external ear	1		
Total	10		

MATERIAL AND METHODS

Between 1989 and 2002 a total of 9 patients with aural atresia were treated in our center, 4 of whom had a unilateral malformation of the external middle ear and 5; a bilateral one. A total of 12 ears were operated on: 3 of the patients had both ears operated on. Prior to surgery all patients underwent an audiometry test and a CT scan of the petrous apex. In 9 cases, tonal liminal audiometry was carried out, evaluating bone and air conduction and the differential tone threshold. In 3 cases, due to the lack of collaboration from the patient due to their short age, an evoked auditory potential (EAP) test was performed instead of tonal liminal audiometry. The results of the EAP are considered equivalent to bone conduction in tonal liminal audiometry. The audiometric tests were carried out a month after surgery and in every follow-up visit.

In every case there was a greater or lesser degree of microtia associated to the agnesis of the EAC. A canalplasty through a retroauricular approach to the atresic plaque lateral to the tympanic cavity was performed. In every case a tympanoplasty was carried out using fascia from the temporal muscle and reconstruction of the ossicular chain with a partial ossicular prosthesis (POP) was only necessary in 3 ears.

The audiometric results were compared before and one month after surgery, (the average air- and bone-conduction thresholds and the differential threshold), correlating these results with the points obtained prior to surgery

from the CT scan as per the Jahrsdoerfer criteria.

For the statistical analysis of the results, we used the SPSS (version 11.0) program. Normality tests, a comparison of averages (t for Student), and the linear correlation of the audiometric results depending on the points obtained in the Jahrsdoerfer classification were all carried out.

RESULTS

Table 2 shows the audiometric results before and after surgery listing the values of air conduction (AC), bone conduction (BC) and air-bone gap (AB gap). We have found that statistically significant differences ($p = 0.003$) exist in the AC before and after surgery and in the AB gap before and after surgery ($p = 0.003$). With regard to AC, differences between the value prior to surgery (35.18 ± 28.17) and after (28.28 ± 20.76) do exist even if they are not statistically significant ($p > 0.005$).

The most significant data in the audiometry is the closure of the air-bone gap following surgery (Figure 1). In order to verify whether any relationship exists between the points obtained in the Jahrsdoerfer classification and the AB gap after surgery, we have carried out a comparison of both parameters and found that a significant linear correlation exists [Spearman correlation coefficient of $-0,764$ ($p = 0.016$)] (Figure 2).

Table 2: Descriptive statistics (Summary of the sample)

	N	Average	Typical deviation
Air conduction before surgery (dB)	9	76.3	20.40
Air conduction after surgery (dB)	9	46.11	11.19
Bone conduction before surgery (dB)	12	35.18	28.17
Bone conduction after surgery (dB)	12	28.27	20.76
Differential tone threshold before surgery (dB)	9	54.44	11.21
Differential tone threshold after surgery (dB)	9	26.52	14.92

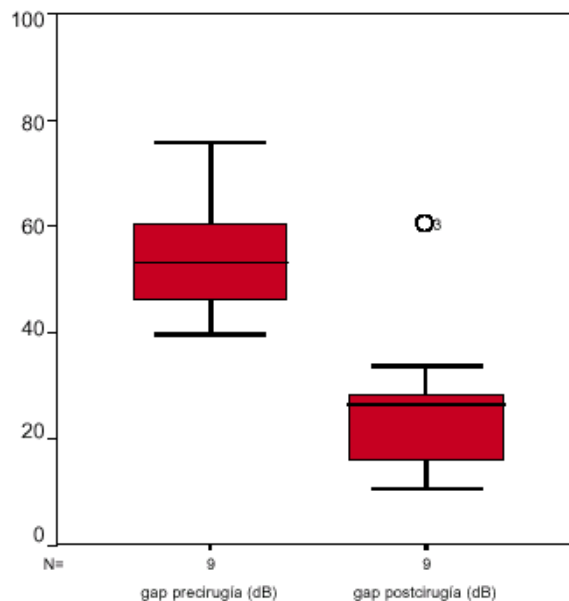


Figure 1. Air-bone gap values before and after surgery.

Regarding complications, there was lateralization of the new tympanic membrane in 16% of cases, (2 ears), partial stenosis of the EAC in 8.3%, (1 ear), and a retroauricular fistula in 8.3% (1 ear). No serious complications, such as facial paralysis or neurosensorial hearing loss, were seen in any of the ears that were operated on.

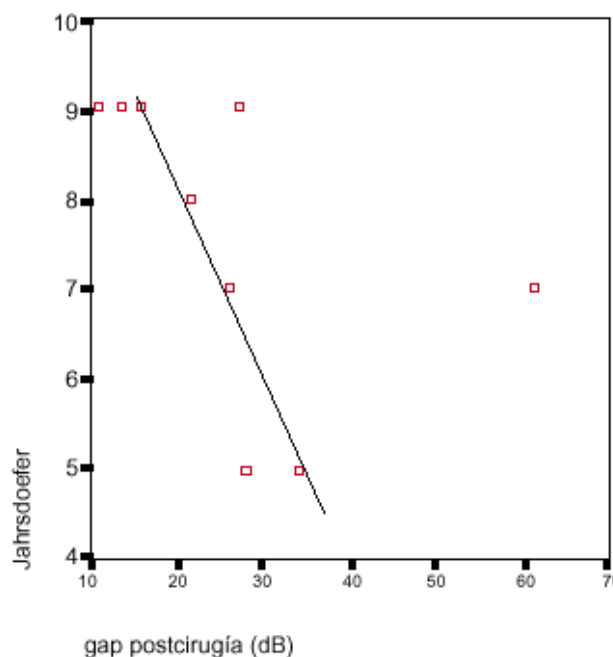


Figure 2. Linear correlation: -0.764 Rho Spearman ($p=0.016$). Jahrsdoerfer score and post-surgical air-bone gap.

DISCUSSION

Imaging evidence of the integrity of the inner ear and verification of the function of the inner ear are two indisputable criteria when considering surgical treatment for aural atresia.

From the imaging point of view, the most important elements when planning surgery are: the degree of pneumatization of the temporal bone; the localization of the facial nerve; the existence of both the oval window and the stapes footplate; and the morphological state of the inner ear¹. The lack of sufficient pneumatization is the most important cause of inoperability. This is a unanimous criterion, it identifies the optimum age for surgery as being from the age of six onwards since that after that age, the mastoids should be sufficiently well-developed and the costal cartilage mature enough to serve in the reconstruction of the earlobe⁵. We recommend first the surgical correction of the microtia followed by surgery on the EAC and the middle ear, given that the retroauricular surgical approach required for the canalplasty could comprise the survival of the future costal cartilage graft (plastic surgery of the microtia), due to a poor blood supply⁶.

Regarding morphological changes of the ossicular chain, the most common finding⁵ is the absence of the handle of the malleus or the fixation of the incudomalleal joint. However, surgery should only take place in cases of discontinuity of the chain (by means of a total or partial prosthesis). The stapes footplate is often intact; its absence however means reconstructive surgery on a second procedure.

Of all the most common possible surgical complications, stenosis in the membranous portion of the EAC is the most precocious⁷ and can require a surgical revision (8.3% in our results); the lateralization of the neotympanic membrane is a later complication (16% in our results) that can, in part, jeopardize the final functional result.

Neurosensory hearing loss and facial paralysis are more serious complications, irreversible, but fortunately uncommon.

Our data shows a good correlation between the final hearing results and the preoperative score obtained in the Jahrsdoerfer classification. If a bad score resulted in an auditory gain better than expected or vice versa, this paradox can be explained looking at the surgeon's learning curve.

Some authors propose that surgery should

be carried out in those cases with: a minimum score of 7 in the Jahrsdoerfer classification¹. In our experience, such a classification is appropriate for determining the prognosis of the hearing results; however, it is difficult to set an exact score from which we should exclude patients from surgery. Focusing on our results, as well as those of other authors⁸, the main help of the Jahrsdoerfer classification is possibly the assessment of the CT scan of the petrous apex when deciding on the surgical options for aural atresia.

In our experience, treatment of both unilateral and bilateral aural atresia should follow a protocol that allows us to provide each patient with the best treatment option. In the case of unilateral aural atresia, the hearing function is evaluated by means of EAP during the first week of life.

If a significant hearing deficit exists, it can be helped by hair-band hearing aids until the age of 5, when we can carry out a CT of the petrous apex to evaluate the likely outcome of possible reconstructive surgery. The plastic reconstruction of the earlobe can be carried out independently of the morphological state of the middle ear and of the mastoids. The aforementioned plastic surgery on the earlobe deformity is carried out after the age of 6 on account of the reasons previously explained. From then on, the reconstruction of the EAC and of the middle ear is decided depending on imaging prognostic factors (Jahrsdoerfer's criteria) and on the integrity of the inner ear regarding hearing. If surgery is not an appropriate option, we prefer the prosthetic adaptation of hearing aids or osseointegrated implants of the BAHA type.

In bilateral aural atresia, the decisions regarding therapy follow a similar plan in terms of the diagnostic tests and intervention times. The prosthetic adaptation of hearing aids is the most suitable option until surgery can be considered. As for unilateral atresia, reconstructive surgery of the earlobe does not limit subsequent interventions, so it can be carried out from the age of 6 should the patient or the patient's family request it. Regarding treatment for the hearing deficit, some authors opt for an osseointegrated implant (BAHA)². However in our experience, reconstructive surgery is the recommended option: for which, the ear with the best prognosis in terms of imaging and hearing criteria should be done first, and if the results are good, after at least 2

years, one should consider to operate on the contralateral ear.

CONCLUSIONS

Aural atresia remains a difficult pathology regarding treatment. The analysis of our results corroborates that appropriate selection of

patients for reconstructive surgery is one of the most important parameters in obtaining satisfactory postoperative results in both unilateral and bilateral atresia. For making decisions about reconstructive treatment for aural atresia, the Jahrsdoerfer classification is very useful in both the imaging diagnosis as well as in determining the hearing prognosis of the ear to be operated on.

REFERENCES

- 1.-Otologic Surgery. Second Edition. Brackmann DE, Shelton C, Arriaga M.5: 54-67. W.B Saunders Company 2001.
- 2-Gastrom G, Bergstrom K, Tjellstrom A. The bone – anchored hearing aid and bone-anchored epithesis for congenital ear malformations. Otolaryngol Head and Neck Surg 1993;109:46-53.
- 3-Jahrsdoerfer RA. Congenital atresia of the ear.Laryngoscope 1978;88 (Suppl 13):1-48.
- 4-Head and Neck Surgery. Robert A. Jahrsdoerfer and Eugenio A. Aguilar Vol.2.(p.50-65) Ed. H.H. Naumann 1996.
- 5-Shih L, Crabtree JA .Long-term surgical results for congenital aural atresia. Laryngoscope 1993;103:1097-1102.
- 6-Siegert R. Combined reconstruction of congenital auricular atresia and severe microtia .Laryngoscope 2003;11
- 2021-7;discussion 2028-9.
- 7-Zim SA. Microtia reconstruction: an update. Curr Opin Otolaryngol Head Neck Surg 2003;11 (4):275-81.
- 8-Lambert PR. Congenital aural atresia: stability of surgical results. laryngoscope 1998;108: 1801-1805.