

Dehiscence of the superior semicircular canal: report of a case and bibliography review

J. Montojo Woodeson, T. Heitzmann, L. Rubio Morales
Unidad ORL. Hospital Ruber Internacional. Madrid.

Abstract: We present a case of deficiency of the superior semicircular canal (SHCD in a 37 years old patient that came to us because of episodes of subjective vertigo in response to intense sounds (Tullio phenomenon). The audiometry, electronistagmography, tympanometry and stapes reflexes were normal and the fistula test was negative. The CT scan showed an absence of bone overlying the superior semicircular canal (SSC) of the right ear and the left ear was normal. When both ears were exposed to intense sounds, only the right one presented vertigo was, without nystagmus.

Key words: Superior semicircular canal. Vertigo. Temporal bone. Tegmental defects. Minor syndrome.

INTRODUCTION

Superior semicircular canal dehiscence (SSCD) was first described by Minor et al. in 1998¹ and was defined as the absence of bone overlying the superior semicircular canal (SSC) in the area closest to the dura mater of the middle cranial fossa².

Some of the known causes of sound induced-vertigo (Tullio's phenomenon) include perilymphatic fistula and congenital syphilis, the latter causes the hyperlaxity of the annular ligament of the stapes footplate^{3,4}. SSCD has been recently described as a new cause of this phenomenon^{1,5}.

A sound-induced vertical-rotational nystagmus which correlates with the affected SSC has been noted in these patients. Likewise, the absence of bone overlying the SSC has been proved by CT of the temporal bone and by an examination using a middle fossa approach. Surgical repair of the corresponding SSC resulted in the

resolution or improvement of the symptoms in the majority of patients included in published works^{1,2,6}. Clinical manifestations of SSCD include vestibular symptoms and signs in one group of patients, vestibular and auditory alterations in another and isolated hearing loss in yet another group⁴.

We present the case of a patient diagnosed as having SSCD and vestibular symptoms. We also present a current bibliographical review of the subject.

CLINICAL CASE

A 37-year-old woman consulted us for the first time four years ago due to "dizziness caused by loud noises". Her medical history indicated that she had been suffering from subjective vertigo in response to sounds of high intensity for a year, along with occasional tinnitus, which had no temporal relationship with the vertigo. There was no hearing loss, otalgia or otorrhea nor were there cervical disturbances. Treatment with ginkgo biloba had been discontinued and her medical history provided nothing further of interest.

Otoscopy, tonal and verbal audiometry, tympanometry and the stapedial reflex were all normal. An examination was completed using BAEP and electronystagmography with a caloric test, with normal results. Radiography of the cervical spine showed an increase in the cervical lordosis.

Two years later the symptoms persisted and were clearly related to exposure to loud noises, mainly affecting the right ear. The electronystagmographic and audiometric tests were repeated but were normal. An examination of the fistula sign was negative. Due to the possibility of a perilymphatic leak or SSCD, a CT of the temporal bones was requested. It showed an absence of bone between the SSC and the middle cranial fossa on the right side with the left side being normal. In an attempt to trigger the typical sound-induced vertical-rotational nystagmus described in patients with SSCD, both ears were subjected to pure tones at 250, 500, 1000, 2000 and 4000 Hz until the patient experienced vertigo or until the maximum output of the audiometry was reached. The results showed that the patient experien-

Correspondence: José Montojo Woodeson
Leopoldo Alas Clarín, 2, 1 ° C -- 28035 Madrid.
E-mail: josemontojo@hotmail.com
Fecha de recepción: 24-2-2004
Fecha de aceptación: 25-10-2004

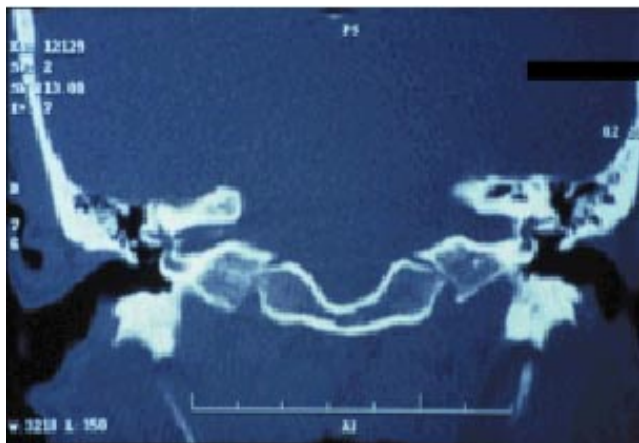


Figure 1. CT coronal cut showing the absence of bone on the superior semicircular canal of the affected ear (on the left side of the image).

ced vertigo with acoustic stimulus of the right ear at 105 dB in 500 Hz, and at 100 dB in 1000, 2000 and 4000 Hz, without experiencing nystagmus with Frenzel glasses or experiencing any vertiginous response from stimulus to the left ear.

DISCUSSION

The first work describing SSCD syndrome as an independent clinical entity is relatively recent and was published by Minor et al in 1998¹. It described a group of eight patients who had shown possible SSCD in CT and who presented vertigo provoked by certain noises or activities which increased intracranial pressure or middle ear pressure (coughing, Valsalva manoeuvre, sneezing etc). Seven of these eight patients showed rotational nystagmus in response to sound stimulus or pressure in the EAC. The nystagmus was in a direction congruous with the stimulus from the SSC of the affected ear. In two of the eight patients surgery confirmed the lack of bone overlying the SSC.

In order to explain the physiopathology of the process, Minor hypothesized that the absence of bone cover overlying the SSC was equivalent to a third window. This allows the movement of the cupula of the SSC to transmit the increase in pressure to the round or oval window, or the increase of intracranial pressure¹.

Minor has also recently included SSCD in the group of labyrinthine fistulae, which share common characteristics with perilymphatic fistulae and the erosion of the labyrinth bone by cholesteatoma or other forms of chronic inflammation of the middle ear⁴. Although the three symptoms can have completely different causes, their physiopathology is common and their clinical manifestations can coincide. All three produce a disruption in the otic capsule, adding a point with increased compliance to the two unique points in

which this occurs in a physiological form, the oval and round windows. The associated symptoms and signs can be understood by basing them on the presence of a third mobile window in the internal ear and the consequent abnormal transmission of pressure to the system^{4,7}. Minor's hypothesis is also supported by experimental models based on laboratory animals^{8,9} and it is currently the most accepted explanation in medical literature.

Other works have concentrated on the attempt to trace the embryological origin of these bone deficiencies, how the bone covering the SSC develops with the normal growth of a child and its prevalence in the general population. In a study by Carey et al of 1,000 temporal bones obtained from autopsy (526 bones from adults and 36 bones from 20 children), the incidence in adults of complete absence of bone overlying the SSC was 0.5%, while 1.4% presented a bone covering clearly thinner than the tests (<0.1mm)¹⁰. In the infant population it was revealed that the bone covering the SSC was very thin and progressively thickened until the age of three. However, there was no explanation for why, in this age group, there were no symptoms despite the thinness of the SSC cover. A study of temporal bones from dogs in various stages of growth also supported the observation of a progressive thickening of the bone covering the SSC¹¹.

Tegmen dehiscence in temporal bones affects between 0-34% of the general population and some authors have noted that the percentage is much higher in patients with SSCD¹²⁻¹⁸. An absence of bone over the geniculate ganglion is also more frequent in patients with SSCD (53%) than in studies of non selected temporal bones (5-15%)¹⁹⁻²¹. The frequent association of SSCD, multiple tegmen defects and the absence of bone over the geniculate ganglion suggest a common etiology. Merchant and McKenna¹⁷ highlight the possibility of multiple defects in cases of surgical closure of a CSF leak at the tegmen level, now that imaging studies generally underestimate the number of defects at this level.

The clinical presentation of SSCD is variable. The most frequent forms of presentation are episodes of vertigo and oscillopsia induced by three possible causes^{1,22,23}.

1. Loud noises (Tullio's phenomenon).
2. Changes in pressure in the EAC transmitted to the middle ear (Hennebert's sign).
3. Valsalva's manoeuvre.

In many of these patients the presence of perilymphatic fistula at the level of the oval or round window or Meniere's disease is suspected before any SSCD diagnosis is made.

Another form of clinical presentation described in several of the most recent works is conductive hearing loss, in an isolated form or together with vestibular

symptoms and signs, although this was not the case in our patient. Some of the patients included in these works have been wrongly diagnosed as suffering otosclerosis^{6,24-26}. In some of these patients conductive hearing loss was the only clinical manifestation of SSCD. As SSCD does not affect the stapedial reflex, an examination of this would distinguish the conductive hearing loss produced by otosclerosis from that produced by SSCD with isolated conductive hearing loss²⁴. Together these three retrospective works²⁴⁻²⁶ describe a total of six patients previously diagnosed with otosclerosis, who were subsequently proven to have SSCD. In four of these a stapedectomy was carried out but none of them improved their hearing, although the authors neither explained if these patients had undergone a stapedial reflex examination nor what the results were if a examination had been done. In one of the patients the SSCD was later sealed using a middle fossa approach and the gap was closed. This clearly supports the causal relationship between the bone defect and the conductive hearing loss. When these patients undergo the Weber test the sound typically lateralizes to the affected ear and some patients hear the tuning fork on the same side as a manifestation of the transmission hyperacusis. In these patients, the best way to explain the difference between the air and bone conduction in the audiometry tests would be that of the presence of a "third window". The SSC dehiscence would provoke a loss or dissipation of acoustic energy through this window, keeping the bone conduction, with the appearance of an audiometric gap and an apparent conductive hearing loss.

The diagnosis of SSCD is based on the clinical history, the results of the physical examination and radiological confirmation²⁸. In the case presented, the patient experienced rotational vertigo when the right ear was stimulated acoustically but we were unable to stimulate any ocular response. This could be due to the short response, to fatigue or to other processes. The presentation of peripheral vertigo without accompanying nystagmus during examination is well documented, as is the case of BPPV. BPPV has been reported in between 22-40% of patients with a clinical history congruous with this process who do not reveal nystagmus during the Dix-Hallpike maneuver. It is thought that the most probable explanation for this phenomenon is the fatigue typical of the BPPV²⁹⁻³¹. We did not consider carrying out the graphic register using ENG or VNG at the same time as the acoustic stimulation as it does not contribute to ensure precision to the examination, given that the sensitivity in the detection of rotational eye movements is greater in direct visualisation (0.1°) than in VNG (0.25°) or ENG ($0.5-1^\circ$)^{32,33}.

Ostrowsy et al describe how the origin of nystagmus in patients with Tullio's phenomenon can be

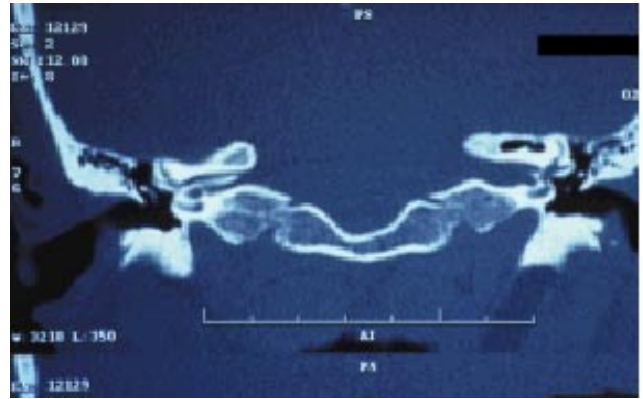


Figure 2. SSCD is frequently associated with other anatomical anomalies at the level of the middle fossa. In the figure we can see a large falciform crest in the internal auditory canal of the affected ear.

deduced using analysis of the three-dimensional vector of the induced nystagmus³⁴. In the case of SSCD, rotational nystagmus is obtained in a clockwise direction which beats downwards, with an amplitude of the turn between 1-7 degrees, that of the vertical component between 1-5 degrees and that of the horizontal component less than 1.5 degrees. Halmagyi et al propose the presentation of clicks at 110 dBs to reproduce nystagmus³⁵ as a rapid screening test in patients with vertigo and suspicion of SSCD.

Cremer et al believe that the main diagnostic test is the three-dimensional record (horizontal, vertical and torsional components) of sound-evoked eye movements and the pressure on the EAC transmitted to the middle ear³⁶. In SSCD, eye movements appear in-line with the dehiscent semicircular canal, although large scale dehiscence with associated hyperfunction in the affected semicircular canal can make it seem that they are aligned with other planes³⁶. The direction of the nystagmus evoked by the changes in pressure in the EAC and by the Valsalva manoeuvre can be predicted based on the direction of the endolymph flow in the interior of the SSC (ampullopetal or ampullofugal flow). This can lead to four situations:

1. Valsalva manoeuvres against pinched nose (introduction of air into the middle ear using the Eustachian tube). This produces a displacement in the direction of the internal ear from the stapes and an ampullofugal flow (excitation) in the SSC.

2. Valsalva manoeuvres against the closed glottis (deep inhalation and thoracic pressure with vocal cords in complete adduction). The increase in intrathoracic pressure reduces the venous return and increases intracranial pressure. The membranous SSC is exposed to this increase in pressure through the bone dehiscence, which induces an ampullopetal flow (inhibitory) in the SSC.

3. The positive pressure in the EAC pushes the tympanic membrane and the stapes towards the inner ear, generating an ampullofugal flow in the SSC.

4. Negative pressure in the EAC produces a movement inverse to that of the previous case, generating an ampullopetal flow in the SSC.

The main tool used to support the diagnosis of SSCD is imaging testing - this is the only non-invasive method which can diagnose bone dehiscence³⁷. The preferred imaging test is high resolution coronal CT, preferably with 0.5 mm cuts, rather than the conventional 1 mm cuts, in order to try and prevent false positives due to the averaging⁴. Cases of SSCD have also been reported in asymptomatic patients, judging by this radiological discovery it is not a coincidence and must be correlated with the clinical history and the exploratory findings³⁸, as in the clinical case we have presented. Merchant and McKenna believe that CT generally underestimates the number of tegmen defects, attributing them to the small size of the defects and the inability of CT to differentiate the true defects of the thinned tegmen¹⁷. Studies using CT have shown that the thickness of bone overlying the intact SSC in patients with unilateral SSCD is significantly thinner than in patients without SSCD³⁹. A recent study evaluated the usefulness of MRI in the diagnosis of SSCD, taking the CT as a reference as this is considered to be the standard test for its diagnosis, and obtaining a sensitivity of 96% and a specificity of 98%⁴⁰.

Another test which has proved useful in the diagnosis of SSCD is that which obtains the vestibular-evoked myogenic potentials⁴¹. This test records the relaxation potentials of short latencies evoked by "clicks" collected using electrodes placed on the skin covering the ipsilateral sternocleidomastoid muscle while it is subject to a tonic contraction^{42,43}. Previous studies have shown that these responses originate in the vestibular system, probably the saccule, and not the cochlea^{42,44,45}. The threshold to evoke these myogenic potentials is less in ears with SSCD than in healthy ears.

The definitive treatment for these patients is surgical and this is appropriate when the patient is incapacitated by the symptoms⁴⁶. In the clinical case we have presented, we did not consider surgery as the symptoms were limited. In the work by Minor where SSCD is described for the first time¹, there was surgical filling of the bone defect in two of the eight patients included in his series with a mix of fascia, bone pate and fibrin tail. Tullio's phenomenon disappeared and the vestibular symptoms improved in both patients, although one of them continued reproducing nystagmus with Valsalva manoeuvre and in the other the fistula test was positive four months after the intervention. Another previously mentioned work by this author, describes the sealing of the SSC using a

middle fossa approach in a patient with conductive hearing loss which achieved a gap closure⁶.

In a bibliographical review published in 2001, Gianoli describes 38 cases of SSCD confirmed by CT, with clinical criteria compatible with this diagnosis². Of the 38 cases included in the review, there was intervention using a middle fossa approach with surgical repair, which confirmed the defect. In two cases the surgical repair consisted of the occlusion of the SSC by transmastoid route, which cured the symptoms. The rest were treated using occlusion by the middle fossa of the dehiscence area using fascia, fibrin tail, skull grafts or hydroxyapatite cement.

A recent study has evaluated the presence of dehiscence not only in the SSC but also in the posterior semicircular canal (PSC)⁴⁷. 507 patients were evaluated, divided into three groups according to symptoms - patients with vertigo (128 patients), patients with sensorineural hearing loss without vertigo (183 patients) and a control group without symptoms related to the inner ear (196 patients). The results showed that the frequency of dehiscence was similar in both canals, as was its distribution in the three groups of patients. The authors concluded that dehiscence of the PSC can produce vertigo in a similar way to SSCD, although they did not clarify if the vertigo would appear in the context of Tullio's phenomenon nor if conductive hearing loss could also exist. Knowledge of the physiopathology of SSCD suggests that both questions would have an affirmative answer. In order to distinguish dehiscence of one canal or the other we should focus on the axis of the nystagmus which, according to Ewald's first law, should coincide with the affected canal⁴⁸.

CONCLUSIONS

Although SSCD has already been defined in its etiopathology, physiopathology and clinical presentation, the review of recent literature shows new and significant discoveries over a short period of time. New forms of presentation (conductive hearing loss) and other alterations with superimposed presentation (PSC dehiscence) make it clear that important questions about definition still remain and make it possible to predict important new discoveries throughout the coming years.

References

1. Minor LB, Solomon D, Zinreich JS, Zee DS. Sound-and/or pressure-induced vertigo due to bone dehiscence of the superior semicircular canal. *Arch Otolaryngol Head Neck Surg* 1998;124(3):249-58.
2. Gianoli GJ. Deficiency of the superior semicircular canal. *Curr Opin Otolaryngol Head Neck Surg* 2001;9:336-41.

3. Tullio P. Das Ohr und die Entstehung der Sprache und Schrift. Berlin: Urban and Schwarzenberg,1929.
4. Minor LB. Labyrinthine fistulae: pathobiology and management. *Curr Opin Otolaryngol Head Neck Surg* 2003;11:340-6.
5. Smullen JL, Andrist EC, Gianoli GJ. Superior semicircular canal dehiscence: a new cause of vertigo. *J La State Med Soc* 1999;151(8):397-400.
6. Minor LB, Carey JP, Cremer PD, Lustig LR, Streubel SO. Dehiscence of bone overlying the superior canal as a cause of apparent conductive hearing loss. *Otol Neurotol* 2003;24:270-8.
7. Rosowski JJ, Songer JE, Nakajima HH, Brinsko KM, Merchant SN. Clinical, experimental, and theoretical investigations of the effect of superior semicircular canal dehiscence. *Otol Neurotol* 2004; 25(3):323-32.
8. Hirvonen TP, Carey JP, Liang CJ, Minor LB. Superior canal dehiscence: mechanisms of pressure sensitivity in a chinchilla model. *Arch Otolaryngol Head Neck Surg* 2001;127(11):1331-6.
9. Carey JP, Hirvonen TP, Hullar TE, Minor LB. Acoustic responses of vestibular afferents in a model of superior canal dehiscence. *Otol Neurotol* 2004;25(3):345-22.
10. Carey JP, Minor LB, Nager GT. Dehiscence or thinning of the bone overlying the superior semicircular canal in a temporal bone survey. *Arch Otolaryngol Head Neck Surg* 2000;126:137-47.
11. Roberto M, Favia A, Lozupone E. Postnatal bone growth in the semicircular canals of the dog. *Italian J Anat Embryol* 1998;103:27-34.
12. Ahren C, Thulin CA. Lethal intracranial complications following inflation in the external auditory canal in the treatment of serous otitis media due to defects in the petrous bone. *Acta Otolaryngol (Stockh)*1965;60:407-21.
13. Lang DV. Macroscopic bony deficiencies of the tegmen tympani in adult temporal bones. *J Laryngol Otol* 1983;97:685-8.
14. Kapur TR, Bangash W. Tegmental and petromastoid defects in the temporal bone. *J Laryngol Otol* 1986;100:1129-32.
15. Ferguson BJ, Wilkins RH, Hudson W, et al. Spontaneous CSF otorrhea from tegmen and posterior fossa defects. *Laryngoscope* 1986;96:635-44.
16. Jahrsdoerfer RA, Richtsmeier WJ, Cantrell RW. Spontaneous CSF otorrhea. *Arch Otolaryngol* 1981;107:257-61.
17. Merchant SN, Mackenna MJ. Neurotologic manifestations and treatment of multiple spontaneous tegmental defects. *Am J Otol* 2000;21:234-9.
18. Tsunoda A, Terasaki O. Dehiscence of the bony roof of the superior semicircular canal in the middle cranial fossa. *J Laryngol Otol* 2002;116(7):514-8.
19. House WF, Crabtree JA. Surgical exposure of the petrous portion of the seventh nerve. *Arch Otolaryngol* 1965;81:506-7.
20. Maquet J. Congenital malformations and middle ear surgery. *J Roy Soc Med* 1981;74:119-28.
21. Minor LB. Superior canal dehiscence syndrome. *Am J Otol* 2000;21(1):9-19.
22. Minor LB, Cremer PD, Carey JP, Della Santina CC, Streubel SO, Weg N. Symptoms and signs in superior canal dehiscence syndrome. *Ann NY Acad Sci* 2001;942:259-73.
23. Rhoton AL, Pulec JL, Hall GM, et al. Absence of bone over the geniculate ganglion. *J Neurosurg* 1968;28:48-53.
24. Halmagyi GM, Aw ST, McGarvie LA, Todd MJ, Bradshaw A, Yavor RA, et al. Superior semicircular canal dehiscence simulating otosclerosis. *J Laryngol Otol* 2003;117(7):553-7.
25. Cox KM, Lee DJ, Carey JP, Minor LB. Dehiscence of bone overlying the superior semicircular canal as a cause of an air-bone gap on audiometry: a case study. *Am J Audiol* 2003;12(1):11-6.
26. Mikulecc AA, McKenna MJ, Ramsey MJ, Rosowski JJ, Herrmann BS, Rauch SD, et al. Superior semicircular canal dehiscence presenting as conductive hearing loss without vertigo. *Otol Neurotol* 2004;25(2):121-9.
27. Watson SRD, Halmagyi GM, Colebatch JG. Vestibular hypersensitivity to sound (Tullio phenomenon): structural and functional assessment. *Neurology* 2000;54:722-8.
28. Brantberg K, Bergenius J, Mendel L, Witt H, Tribukait A, Ygge J. Symptoms, findings and treatment in patients with dehiscence of the superior semicircular canal. *Acta Otolaryngol* 2001;121(1):68-75.
29. González del Pino B, Pérez Fernández N. Discapacidad en pacientes con vértigo posicional paroxístico benigno del canal semicircular posterior. *Acta Otorrinolaringol Esp* 2003;54:401-8.
30. Haynes DS, Resser JR, Labadie RF, Girasole CR, Kovach BT, Schecker LE, et al. Treatment of benign positional vertigo using the Semont maneuver: efficacy in patients presenting without nystagmus. *Laryngoscope* 2002;112:796-801.
31. Tirelli G, D'Orlando E, Giancomarra V, Russolo M. Benign positional vertigo without detectable nystagmus. *Laryngoscope* 2001;111:1053-6.
32. Denia Lafuente A. Pruebas funcionales vestibulares: métodos de registro de movimientos oculares. En: *Vértigo y desequilibrio*. Barcelona: Almirall Prodesfarma, S.A., 2000:19-26.
33. Coats AC. Electronystagmography. En: *Physiological measures of the audio-vestibular system*. New York: Academic Press Inc., 1975:37-85.
34. Ostrowski VB, Byskosh A, Hain TC. Tullio Phenomenon with dehiscence of the superior semicircular canal. *Otol Neurotol* 2001;22(1):61-5.
35. Halmagyi GM, McGarvie LA, Aw ST, Yavor RA, Todd MJ. The click-evoked vestibulo-ocular reflex in superior semicircular canal dehiscence. *Neurology* 2003;60(7):1172-5.
36. Cremer PD, Minor LB, Carey JP, Della Santina CC. Eye movements in patients with superior canal dehiscence syndrome align with the abnormal canal. *Neurology* 2000;55(12):1833-41.
37. Belden CJ, Weg N, Minor LB, Zinreich SJ. CT evaluation of bone dehiscence of the superior semicircular canal as a cause of sound-and/or pressure-induced vertigo. *Radiology* 2003;226(2):337-43.

38. Williamson RA, Vrabec JT, Coker NJ, Sandlin M. Coronal computed tomography prevalence of superior semicircular canal dehiscence. *Otolaryngol Head Neck Surg* 2003;129(5):481-9.
39. Hirvonen TP, Weg N, Zinreich SJ, Minor LB. High-resolution CT findings suggest a developmental abnormality underlying superior canal dehiscence syndrome. *Acta Otolaryngol* 2003;123(4):477-81.
40. Krombach GA, Schmitz-Rode T, Haage P, DiMartino E, Prescher A, Kinzel S, et al. Semicircular canal dehiscence: comparison of T2-weighted turbo spin-echo MRI and CT. *Neuroradiology* 2004;46(4):326-31.
41. Brantberg K, Bergenius J, Tribukait A. Vestibular-evoked myogenic potentials in patients with dehiscence of the superior semicircular canal. *Acta Otolaryngol* 1999;119(6):633-40.
42. Colebatch JG, Halmagyi GM, Skuse NF. Myogenic potentials generated by a click-evoked vestibulocollic reflex. *J Neurol Neurosurg Psychiatry* 1994;57:190-7.
43. Ferber-Viart C, Dubreuil C, Duclaux R. Vestibular evoked myogenic potentials in humans: a review. *Acta Otolaryngol* 1999;119:6-15.
44. Ozeki H, Matsuzaki M, Murofushi T. Vestibular evoked myogenic potentials in patients with bilateral profound hearing loss. *ORL J Otorrhinolaryngol Relat Spec* 1999;61:80-3.
45. Murofushi T, Halmagyi GM, Yavor RA, Colebatch JG. Absent vestibular evoked myogenic potentials in vestibular neurolabyrinthitis: an indicator of inferior vestibular nerve involvement? *Arch Otolaryngol Head Neck Surg* 1996;122:845-8.
46. Martin JE, Neal CJ, Monacci WT, Eisenman DJ. Superior semicircular canal dehiscence: a new indication for middle fossa craniotomy. Case report. *J Neurosurg* 2004;100(1):125-7.
47. Krombach GA, DiMartino E, Schmitz-Rode T, Prescher A, Haage P, Kinzel S, et al. Posterior semicircular canal dehiscence: a morphologic cause of vertigo similar to superior semicircular canal dehiscence. *Eur Radiol* 2003;13(6):1444-50.
48. Cremer PD, Migliaccio AA, Pohl DV, Curthoys IS, Davies L, Yavor RA, et al. Posterior semicircular canal nystagmus is conjugate and its axis is parallel to that of the canal. *Neurology* 2000;54(10):2016-20.